

Posterior Vitreous Detachment (PVD) is a natural change that occurs during adulthood, when the vitreous gel that fills the eye separates from the retina, the light-sensing nerve layer at the back of the eye.

Symptoms of a PVD include:

- Floaters (mobile blurry shadows that obscure the vision)
- Flashes (streaks of light, usually at the side of the vision)

These symptoms usually become less intense over several weeks.

Most patients experience PVD after age 60, once in each eye, and the condition is usually non-sight-threatening but occasionally affects vision more permanently in the event of complication, such as **retinal detachment** or **epiretinal membrane**.

Causes: Over time, the vitreous gel that fills the eye becomes liquid and condenses (shrinks) due to age and normal wear and tear. Eventually it cannot fill the whole volume of the eye's vitreous cavity (which remains the same size during adulthood) and so the gel separates from the retina, located at the very back of the eye cavity.

Over the next 1 to 3 months, the vitreous gel further condenses and the sides of the gel also separate from the retina until the PVD is complete and the vitreous gel is attached to the retina only at the vitreous base (see *Figure 1*). Clear vitreous fluid fills the space between the condensed vitreous gel and the retina.

If a PVD progresses gently, gradually, and uniformly, the symptoms are typically mild. However, if the forces of separation are strong or concentrated in a particular part of the retina, or if there is an abnormal adhesion (sticking together) between the vitreous gel and the retina (such as **lattice degeneration**), the PVD can tear the retina or a retinal blood vessel.

Flashes and floaters are typically more obvious when PVD is complicated by a **retinal tear** or **vitreous hemorrhage**. These conditions can lead to further complications, such as **retinal detachment** or **epiretinal membrane**, which can result in permanent vision loss. However, about 85% of patients who experience PVD never develop complications and in most cases, the flashes and floaters subside within 3 months.

Diagnostic Testing: Posterior vitreous detachment is usually diagnosed with a dilated eye examination. However, if the vitreous gel is very clear, it may be

continued next page

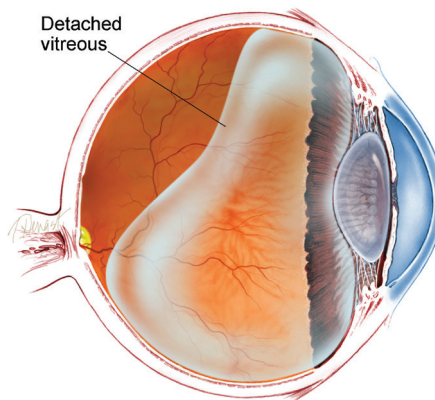


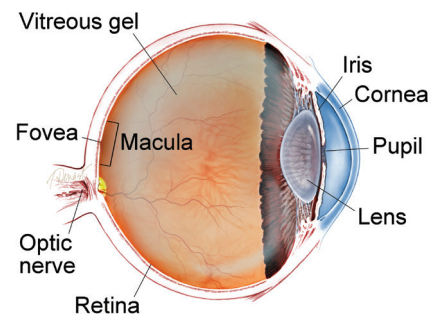
Figure 1
Diagram of the vitreous cavity during posterior vitreous detachment.

SYMPTOMS IN DETAIL

Mild floaters in the vision are normal, but a sudden increase in floaters is often the first symptom of PVD. Floaters are most bothersome when near the center of vision and less annoying when they settle to the side of the vision. They may appear like cobwebs, dust, or a swarm of insects — or in the shape of a circle or oval, called a *Weiss ring*.

During PVD, floaters are often accompanied by flashes, which are most noticeable in dark surroundings. Most patients experience floaters and flashes during the first few weeks of a PVD, but in some cases the symptoms are hardly noticeable. If PVD is complicated by vitreous hemorrhage, retinal detachment, epiretinal membrane, or **macular hole**, the flashes and floaters may be accompanied by decreased or distorted vision. ●

WHAT IS THE RETINA?



THE RETINA is a thin layer of light-sensitive nerve tissue that lines the back of the eye (or vitreous) cavity. When light enters the eye, it passes through the iris to the retina where images are focused and converted to electrical impulses that are carried by the optic nerve to the brain resulting in sight.

Posterior Vitreous Detachment continued from previous page

hard to see the PVD without additional testing, such as **optical coherence tomography (OCT)** (Figure 2a) or **ocular ultrasound** (Figure 2b).

Treatment and Prognosis: PVD is non-sight-threatening and the symptoms subside in the vast majority of patients. Most patients no longer notice flashes or floaters 3 months later, and no treatment or further checkups are needed at that time. Complications of PVD are rare but can be serious and require urgent treatment, such as laser for a retinal tear or surgery for a retinal detachment. For this reason, one or more checkups are recommended within 3 months after the onset of PVD. Rarely, the floaters from PVD persist, and **vitrectomy surgery** to remove the floaters is effective; you and your doctor may consider this after discussing the risks and benefits of surgery. ●

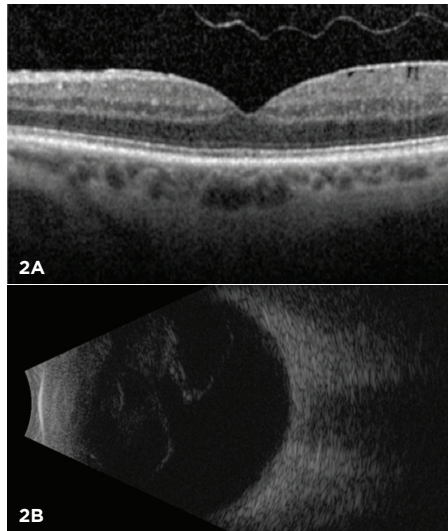


Figure 2
Most posterior vitreous detachments can be diagnosed with a dilated eye exam. However, OCT (A) and B-scan ultrasound (B) are diagnostic tests that can be helpful in diagnosing PVD.

RISK FACTORS

Posterior vitreous detachment is rare in people under the age of 40, and increasingly common during advanced age.

Additional risk factors for PVD include myopia (nearsightedness), trauma, and recent eye surgery such as a **cataract** operation. Patients who experience PVD in one eye will often experience PVD in the other eye within 1 year. ●

THANK YOU TO THE RETINA HEALTH SERIES AUTHORS

Sophie Bakri, MD
Audina Berrocal, MD
Antonio Capone, Jr., MD
Netan Choudhry, MD, FRCS-C
Thomas Ciulla, MD, MBA
Pravin Dugel, MD
Geoffrey Emerson, MD, PhD
Roger Goldberg, MD, MBA
Vincent Hau, MD, PhD
Suber Huang, MD, MBA
Mark Humayun, MD, PhD
Ali Khan, MD
Anat Loewenstein, MD
Mathew MacCumber, MD, PhD
Maya Maloney, MD
Hossein Nazari, MD
Oded Ohana, MD, MBA
George Parlitsis, MD
Jonathan Prenner, MD
Gilad Rabina, MD
Carl Regillo, MD, FACS
Andrew Schachat, MD
Allen Verne, MD
Yoshihiro Yonekawa, MD

EDITOR

John T. Thompson, MD

MEDICAL ILLUSTRATOR

Tim Hengst

Clinical Terms (appearing green within fact sheet text)

Cataract: A clouding of the eye's lens causing a decrease in vision. Cataracts are the most common cause of vision loss for those over the age of 40.

Epi-retinal membrane/Macular pucker: A layer of scar tissue that forms on the surface of the **macula** that can warp and contract causing a wrinkling of the retina and distorted or decreased vision.

Lattice degeneration: An abnormal thinning of the **peripheral retina**. There may be abnormal adhesion of the vitreous gel to the lattice degeneration, causing retinal tears when the vitreous separates from the eye.

Macula: A small area at the center of the retina where light is sharply focused to produce the detailed color vision needed for tasks such as reading and driving.

Macular hole: A hole in the **macula**, which is the small area at the center of the retina where light is sharply focused to produce the detailed color vision needed for tasks like reading. A full-thickness defect in the macula is referred to as a *macular hole*.

Ocular ultrasound: A non-invasive imaging technique that uses high-frequency sound waves to produce images of the eye's structure for physician evaluation. Ultrasound can also be used to measure structures in the eye.

Optical coherence tomography (OCT): A non-invasive imaging technique that uses light to create a 3-dimensional image of your eye for physician evaluation.

Peripheral retina: The area outside of the central retina. This includes the equatorial and anterior retina.

Retinal detachment: A condition where the retina separates from the back of the eye wall. This may be caused by vitreous fluid leaking through a retinal tear or hole and collecting under the retina, causing it to separate from the tissue around it.

Retinal holes/Retinal tears: Breaks or defects in the retina.

Vitreous hemorrhage: A leakage of blood into the gel that fills the eye cavity (also called vitreous humor), often the result of abnormal blood vessels or traction on blood vessels in the retina.

Vitrectomy surgery: A procedure undertaken by a specialist where the vitreous gel that fills the eye cavity is removed to provide better access to the retina. This allows for a variety of repairs, including the removal of scar tissue, laser repair of retinal detachments and treatment of macular holes. Once surgery is complete, a gas bubble or silicone oil may be injected into the vitreous gel to help hold the retina in position.