

Branch Retinal Vein Occlusion Retinal vein occlusions occur when there is a blockage of veins carrying blood with needed oxygen and nutrients to the nerve cells in the retina. A blockage in the retina’s main vein is referred to as a *central retinal vein occlusion* (CRVO), while a blockage in a smaller vein is called a *branch retinal vein occlusion* (BRVO).

Causes: Most BRVOs occur at an *arteriovenous* crossing—an intersection between a retinal artery and vein. These vessels share a common *sheath* (connective tissue), so when the artery loses flexibility, as with atherosclerosis (hardening of the arteries), the vein is compressed.

The narrowed vein experiences turbulent blood flow that promotes clotting, leading to a blockage or *occlusion*. This obstruction blocks blood drainage and may lead to fluid leakage in the center of vision (**macular edema**) and **ischemia**—poor perfusion (flow) in the blood vessels supplying the **macula**.

Risk Factors: The common risk factors for BRVO are:

- Uncontrolled high blood pressure
- Being overweight or obese (increased body mass index)
- Cardiovascular (heart) disease
- **Glaucoma**
- In younger patients who suffer BRVO, an abnormal tendency to develop blood clotting is also possible

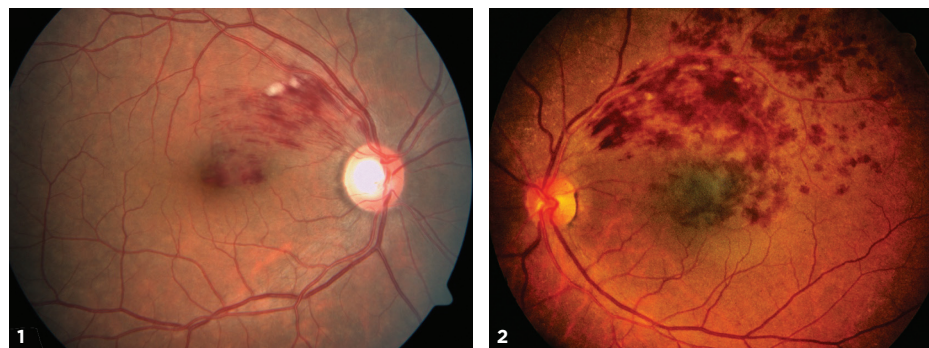
Diagnostic Testing: Most often, BRVO is diagnosed by an eye exam that shows retinal hemorrhage (blood vessels leaking into the retina), thickened and twisted blood vessels, and retinal edema (swelling with fluid).

Two types of retinal imaging tests aid the diagnosis of BRVO:

- **Fluorescein angiography (FA)**
- **Optical coherence tomography (OCT)**

FA provides images of fluid leaking from damaged or abnormal retinal vessels, demonstrating:

- Venous stasis (congestion and slowing of circulation)
- Edema (swelling with fluid)
- Ischemia (inadequate blood supply) or
- Retinal **neovascularization** (abnormal growth of new blood vessels in the retina)



1

2

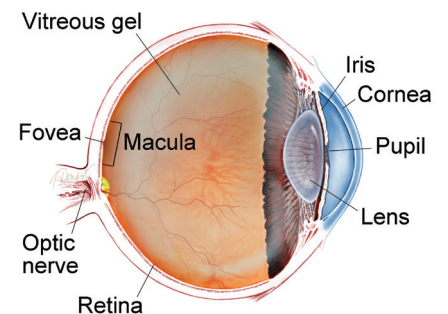
continued next page

SYMPTOMS

BRVO causes a sudden, painless loss of vision. If the affected area is not in the center of the eye, BRVO can go unnoticed with no symptoms.

In rare cases of an undetected vein occlusion, visual **floaters** from a vitreous hemorrhage (blood vessels leaking into the vitreous gel of the eye) can be the main symptom; this is caused by development of abnormal new blood vessels (*neovascularization*) in the retina. ●

WHAT IS THE RETINA?



THE RETINA is a thin layer of light-sensitive nerve tissue that lines the back of the eye (or vitreous) cavity. When light enters the eye, it passes through the iris to the retina where images are focused and converted to electrical impulses that are carried by the optic nerve to the brain resulting in sight.

Figure 1

Branch retinal vein occlusion: Retinal hemorrhage in only a sector of the retina is seen. Cotton-wool spots (white lesions amid the hemorrhages) signify focal ischemia (inadequate blood supply). Foveal edema (swelling with fluid) is also present. Photo courtesy Anat Loewenstein, MD

Figure 2

BRVO with macular edema. David Callanan, MD, Texas Retina Associates. BRVO/CHRPE. Retina Image Bank 2014; Image 15926. © American Society of Retina Specialists.

BRVO *continued from previous page*

OCT provides detailed images of the central retina, allowing detection of macular edema and fluid outside the macula (*Figure 3*).

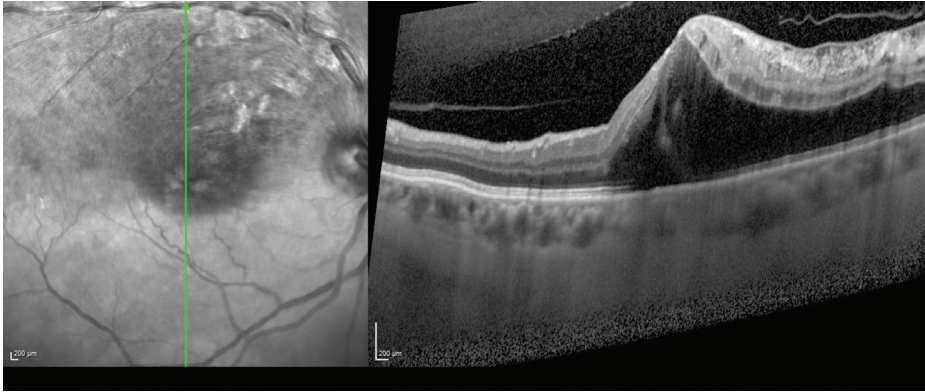


Figure 3
OCT image of macular edema secondary to BRVO. There is a cystoid macular edema mainly in the superior part of the macula, effecting the superior temporal vein.
Photo courtesy of Anat Loewenstein, MD

FA is very valuable for detecting BRVO and the flow of the blood vessels. Once BRVO has been found, OCT is used to provide a better assessment of whether macular edema is present, and if so, how severe it is.

Treatment and Prognosis: Treatment begins with identifying underlying risk factors and treating them. Risk factors are assessed using several methods:

- Blood pressure monitoring
- Determining if blood cholesterol or lipid levels are elevated
- Blood tests, if appropriate, to determine if there is an abnormal tendency to form blood clots

Eye treatment is aimed at treating retinal complications rather than at trying to relieve the blockage itself. Macular edema, the main reason for visual loss from BRVO, is often treated with intraocular (in-the-eye) injections of **anti-VEGF drugs** designed to stop the growth of abnormal new blood vessels in the eye and decrease leakage. Local anesthetic eye drops are given before the injections to numb the eye and minimize discomfort.

There are currently 3 anti-VEGF drugs:

- Avastin® (bevacizumab®)
- Lucentis® (ranibizumab®)
- Eylea® (aflibercept®)

In several large clinical studies, all 3 of these anti-VEGF drugs have demonstrated good results, with over 50% of patients enjoying significant visual improvement. The use of these drugs may require frequent retreatment, but injection schedules are determined on a case-by-case basis.

Laser treatment may be used along with anti-VEGF therapy in hard-to-treat cases. Laser therapy for macular edema involves applying light laser pulses to the macula in a grid pattern. In a large multi-center clinical trial, after 3 years of follow up, this treatment showed improvement of vision in approximately two-thirds of patients.

Intraocular injections of steroids are another potential treatment for eyes that don't respond to anti-VEGF drugs. A clinical trial that evaluated steroid

continued next page

COMPLICATIONS

Retinal neovascularization is a potentially serious complication of BRVO in which an inadequate blood supply (ischemia) causes abnormal new blood vessels to grow on the surface of the retina. This growth can further decrease vision by causing **vitreous hemorrhage** that causes floaters and loss of vision, **retinal detachment**, and glaucoma.

When neovascularization develops, *scatter laser photocoagulation* therapy is used to create burns in the area of the vein occlusion (blockage). The aim is to try to lower the oxygen demand of the retina and thus stop the abnormal blood vessels from growing. Patients receive an anesthetic to numb the eye and make the treatment more comfortable.

Scatter photocoagulation has been shown to reduce neovascularization-related complications from 60% to 30%. Because only a few patients develop abnormal new blood vessels in the retina, not many need scatter photocoagulation treatment. ●

BRVO *continued from previous page*

treatment using a slow-releasing steroid implanted in the eye (dexamethasone or Ozurdex®), showed that approximately 30% of BRVO patients enjoyed significant visual improvement following treatment.

While intraocular steroids can have some side effects such as an increase in eye pressure and cataract progression, in most cases, these side effects can be controlled.

Overall, BRVO carries a generally good prognosis. In fact, some BRVO patients don't require treatment at all, either because the blockage did not involve the macula, or because they have not experienced a decrease in vision. Over 60% of patients, treated and untreated, maintain vision better than 20/40 after 1 year. ●

Clinical Terms *(appearing green within fact sheet text)*

Anti-VEGF drugs: Elevated vascular endothelial growth factor (VEGF), a soluble factor that can be produced in eyes with poor circulation can lead to swelling and the growth of abnormal new blood vessels in the eye. Leaky blood vessels cause swelling such as macular edema and are prone to bleeding, both of which cause decreased vision. Anti-VEGF drugs which inactivate VEGF have revolutionized treatment allowing retina specialists to reduce new blood vessel growth and swelling with periodic injections of anti-VEGF drugs including bevacizumab (Avastin®), ranibizumab (Lucentis®), and aflibercept (Eylea®).

Floater: Mobile blurry shadow that partially obscures vision. Floaters are most bothersome when near the center of vision and less annoying when they settle to the side of the vision. They may appear like cobwebs, dust, or a swarm of insects—or in the shape of a circle or oval, called a *Weiss ring*.

Fluorescein angiography (FA): An imaging technique where a yellow dye called *sodium fluorescein* is injected into a vein in the arm, allowing a special camera to record circulation in the retina and *choroid* in the back of the eye. This test can be very useful in diagnosing a number of retinal disorders.

Glaucoma: A condition where fluid buildup in the eye causes an increase in eye pressure that damages the optic nerve.

Ischemia: Insufficient blood supply to an organ or part of the body such as the retina.

Macula: A small area at the center of the retina where light is sharply focused to produce the detailed color vision needed for tasks such as reading and driving.

Macular Edema: The term used for swelling in the macula in eyes, or the center part of the retina which is responsible for providing the sharp, straight-ahead vision used for reading and recognizing faces as well as color vision.

Neovascularization: Excessive growth of new blood vessels on abnormal tissue as a result of oxygen deprivation that can cause vision loss.

Optical coherence tomography (OCT): A non-invasive imaging technique that uses light to create a 3-dimensional image of your eye for physician evaluation.

Retinal detachment: A condition where the retina separates from the back of the eye wall. This may be caused by vitreous fluid leaking through a retinal tear or hole and collecting under the retina, causing it to separate from the tissue around it.

Retinal vein occlusions: Complication that occurs when there is a blockage of veins carrying deoxygenated blood back from the retinal arteries to the optic nerve. A blockage in the retina's main draining vein is referred to as a central retinal vein occlusion (CRVO), while a blockage in a smaller vein is called a branch retinal vein occlusion (BRVO).

Vitreous hemorrhage: A leakage of blood into the gel that fills the eye cavity (also called *vitreous humor*), often the result of abnormal blood vessels or traction on blood vessels in the retina.

THANK YOU TO THE RETINA HEALTH SERIES AUTHORS

Sophie Bakri, MD
Audina Berrocal, MD
Antonio Capone, Jr., MD
Netan Choudhry, MD, FRCS-C
Thomas Ciulla, MD, MBA
Pravin Dugel, MD
Geoffrey Emerson, MD, PhD
Roger Goldberg, MD, MBA
Vincent Hau, MD, PhD
Suber Huang, MD, MBA
Mark Humayun, MD, PhD
Ali Khan, MD
Anat Loewenstein, MD
Mathew MacCumber, MD, PhD
Maya Maloney, MD
Hossein Nazari, MD
Oded Ohana, MD, MBA
George Parlitsis, MD
Jonathan Prenner, MD
Gilad Rabina, MD
Carl Regillo, MD, FACS
Andrew Schachat, MD
Allen Verne, MD
Yoshihiro Yonekawa, MD

EDITOR

John T. Thompson, MD

MEDICAL ILLUSTRATOR

Tim Hengst